

The neural correlates of spatial language in English and American Sign Language: a PET study with hearing bilinguals

Karen Emmorey,^{a,*} Thomas Grabowski,^b Stephen McCullough,^a Laura L.B. Ponto,^b Richard D. Hichwa,^b and Hanna Damasio^{a,b}

^aLaboratory for Cognitive Neuroscience, The Salk Institute for Biological Studies, 10010 North Torrey Pines Road, La Jolla, CA 92037, USA

^bUniversity of Iowa, USA

Received 10 June 2004; revised 28 September 2004; accepted 6 October 2004
Available online 23 November 2004

Rather than specifying spatial relations with a closed-class set of prepositions, American Sign Language (ASL) encodes spatial relations using space itself via classifier constructions. In these constructions, handshape morphemes specify object type, and the position of the hands in signing space schematically represents the spatial relation between objects. A [¹⁵O]water PET study was conducted to investigate the neural regions engaged during the production of English prepositions and ASL locative classifier constructions in hearing subjects with deaf parents (ASL-English bilinguals). Ten subjects viewed line drawings depicting a spatial relation between two objects and were asked to produce either an ASL locative classifier construction or an English preposition that described the spatial relation. The comparison task was to name the figure object (colored red) in either ASL or in English. Describing spatial relations in either ASL or English engaged parietal cortex bilaterally. However, an interaction analysis revealed that right superior parietal cortex was engaged to a greater extent for ASL than for English. We propose that right parietal cortex is involved in the visual–motoric transformation required for ASL. The production of both English prepositions and ASL nouns engaged Broca's area to a greater extent than ASL classifier constructions. We suggest that Broca's area is not engaged because these constructions do not involve retrieval of the name of an object or the name of a spatial relation. Finally, under the same task conditions, only left parietal activation was observed for monolingual English speakers producing spatial prepositions (H. Damasio et al., 2001, *NeuroImage*, 13). We conclude that the right hemisphere activation observed for ASL-English bilinguals was due to their life-long experience with spatial language in ASL.

© 2004 Elsevier Inc. All rights reserved.

Keywords: English; Bilingual; Sign language

Introduction

To linguistically represent and encode the visual world (i.e., to talk about what we see) requires a crucial interface between language and spatial cognition. Signed languages provide unique insight into this interface because physical space is used to schematically encode spatial relationships. In American Sign Language (ASL), as well as in many other signed languages, locative information is most often expressed via *classifier constructions* in which handshape morphemes specify object type and the position of the hands in signing space schematically represents the spatial relation between objects (see papers in Emmorey, 2003). In contrast, spoken languages tend to express spatial information through prepositions, postpositions, or locative affixes. Prepositions and other locative morphemes are categorical and do not specify spatial relations in a gradient or analogue manner (Talmy, 2000). In contrast, there is an analogue (but nonmetric) relationship between the location of the hands in signing space and the location of objects in a scene, as illustrated in Fig. 1. This iconic mapping allows signers to easily express gradient spatial information (Emmorey and Herzig, 2003). We hypothesize that language modality may partially alter the neural systems involved in the retrieval of linguistic expressions that refer to spatial relations. We investigated this hypothesis by comparing the production of spatial language in English and in ASL by hearing ASL-English native bilinguals.

In previous positron emission tomography (PET) studies, we separately investigated the production of English prepositions by monolingual English speakers (Damasio et al., 2001) and the production of locative classifier constructions by deaf native ASL signers (Emmorey et al., 2002). In these studies, subjects viewed line drawings depicting a spatial relation between two objects (e.g., a paintbrush in a cup) and were asked to describe the spatial relation with either an English preposition or an ASL classifier construction and to name the figure object, which was colored in red (see Fig. 1A). Compared to naming objects, describing spatial relations with ASL classifier constructions engaged parietal cortex bilaterally. The activation within left parietal cortex was similar to

* Corresponding author. Fax: +1 858 452 7052.

E-mail address: emmorey@salk.edu (K. Emmorey).

Available online on ScienceDirect (www.sciencedirect.com).

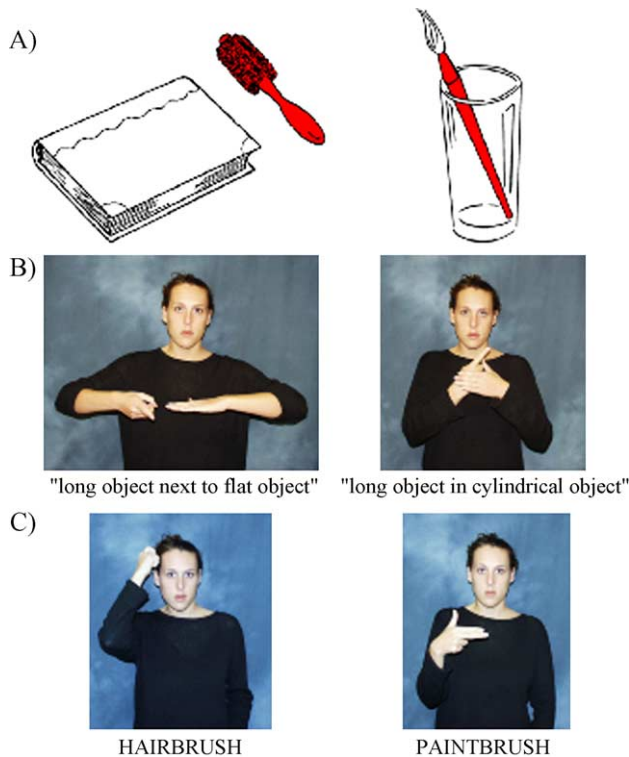


Fig. 1. Illustrations of (A) sample stimuli, (B) ASL locative classifier constructions depicting the spatial relations in (A), and (C) ASL nouns denoting the figure objects in (A).

that observed for English speakers producing prepositions, although for ASL classifier constructions, activation within the left supramarginal gyrus was superior and mesial to that observed for English speakers. For English speakers, the contrast between naming spatial prepositions and naming objects did not reveal significant regions of activation within the right hemisphere. However, when English speakers were required to focus on the spatial relation itself because the objects in the scene were non-nameable, right parietal activation was observed, with an activation maximum quite similar to that found for ASL locative classifier constructions (English: +34, -45, +39; ASL: +31, -50, +43). Right parietal cortex may be activated when a detailed spatial analysis is required to produce the appropriate linguistic encoding. For English speakers, the presence of nameable objects may engage only the left hemisphere because the choice of preposition can depend upon the object, rather than spatial analysis. For example, the preposition *on* is used in English for a ring on a finger, even though the spatial relationship fits the canonical meaning of *around*.

Parietal regions of the cortex in both hemispheres have long been known to be involved in the attention to and perception of the spatial location of physical objects in the environment (e.g., Posner and Petersen, 1990; Ungerleider and Mishkin, 1982). With respect to language, parietal regions may be uniquely engaged during the production and comprehension of everyday spatial language in signed languages. For example, MacSweeney et al. (2002) found enhanced activation in left inferior and superior parietal lobules when deaf and hearing signers comprehended topographic sentences in British Sign Language (e.g., "The cat sat on the bed"), compared to non-topographic sentences ("The boy laughed at the story"). The task was to detect a semantic anomaly. In topographic sentences,

locations in signing space convey specific spatial information, whereas in non-topographic sentences, locations in signing space primarily perform a referential function, conveying little or no spatial information (see Emmorey et al. (1995) for discussion). The activation peak within the left inferior parietal lobule for the topographic sentences was within 10 mm of the activation peak observed by Emmorey et al. (2002) for the production of locative classifier constructions (although the activation was more lateral for the deaf signers in MacSweeney et al.'s (2002) study). Crucially, MacSweeney et al. (2002) found no parietal activation when English translations of the BSL sentences were presented to hearing speakers. Thus, the left parietal activation for signers was most likely due to factors related to language modality (e.g., the use of signing space to represent physical space), rather than to the spatial-semantic features of the topographic sentences.

With respect to language production and parietal activation, Braun et al. (2001) found that hearing ASL-English bilinguals exhibited more activation in left inferior and superior parietal lobules when producing autobiographical narratives in ASL than in spoken English. However, the narratives were not constrained to express spatial information, and the left parietal activation observed by Braun et al. (2001) was much more anterior than the activation observed for the production of spatial descriptions observed by Emmorey et al. (2002) or by MacSweeney et al. (2002) for the comprehension of topographic sentences. Neither Braun et al. (2001) nor MacSweeney et al. (2002) reported any evidence of *right* parietal activation. This suggests that the right parietal activation observed by Emmorey et al. (2002) was due to the specific use of locative classifier constructions to depict spatial scenes.

To depict a spatial scene using classifier constructions, signers must analyze the spatial relation between concrete objects in enough detail to transform this relation into a body-centered manual representation in which each articulator represents an object within the spatial relation. Such visual-motoric transformations are not required when spatial information is expressed via closed-class, noniconic elements such as prepositions or locative affixes. For example, unlike ASL locative classifier constructions, there is no way to phonologically alter an English preposition to mean "above and to the left" or "above and slightly to the left". In ASL, such spatial information is expressed simply by adjusting where the hands are placed in signing space within a locative classifier construction. For ASL signers, right parietal cortex may be routinely engaged for everyday spatial language. For English speakers, however, right parietal cortex may be more engaged when the linguistic system can provide no information about preposition choice because the objects are non-nameable, and preposition selection must therefore rely solely on spatial analysis.

Another important distinction between English prepositions and ASL classifier constructions is that English prepositions provide very little information about the geometric or semantic properties of the figure and ground objects within the specified spatial relation. For example, the English preposition *on* requires only that the ground object have a surface that can support and make contact with a figure object, which can be of any shape. In contrast, the classifier handshape morphemes within an ASL locative classifier construction specify the specific type of object involved in the spatial relation, for example, a long thin horizontally oriented object, a long thin vertically oriented object, a flat horizontal surface, a cylindrical object (see Fig. 1B). The spatial relationship itself is not specified by a morpheme, but by the placement of the

hands with respect to each other in signing space. The non-dominant hand represents the ground (or reference) object and the dominant hand represents the figure (or located) object. Our previous neuroimaging data indicated that the production of ASL locative classifier constructions engaged left inferior temporal (IT) cortex, unlike the production of either English prepositions or ASL prepositions (these are lexical locatives in which handshape is lexically fixed and does not specify object type) (Emmorey et al., 2002; Damasio et al., 2001). This activation maximum observed within left IT was similar to that observed when either speakers or signers named manipulable concrete objects. We suggest that activation within left IT is due to retrieval of the classifier handshape morpheme specifying figure object type.

In the current study, we directly compared the production of spoken English prepositions and ASL locative classifier constructions within the same individual. The participants in this study all had deaf signing parents and acquired ASL as a first language. In addition, they all had normal hearing and were native English speakers, acquiring spoken English from hearing relatives, friends, and the surrounding English-speaking community. The picture stimuli used in this experiment depict everyday spatial relationships between concrete, nameable objects (see Fig. 1A). We hypothesize that describing these spatial relationships will engage the left, but not the right, inferior parietal lobule for English prepositions, whereas the production of ASL locative classifier constructions will engage parietal cortex bilaterally. In addition, we hypothesize that the retrieval of object names in comparison to the retrieval of English prepositions will result in activation within left inferior temporal cortex, but this same comparison in ASL will reveal no significant activation in left IT because both name retrieval and the retrieval of classifier handshape morphemes are hypothesized to engage left IT.

Methods

Subjects

Ten right-handed, hearing native signers were studied under a PET protocol using [^{15}O]water. The subjects were five men and five women, aged 19–41 (mean age = 28 years), with 12 years or more of formal education. All participants had deaf parents and acquired ASL as their first language from birth. All subjects continue to use ASL in their daily lives, and six are professional ASL interpreters. The signing skill of each subject was reviewed by a native signer, and all were judged to be fluent, using an appropriate range of ASL grammatical devices, including classifier constructions. In addition, nine subjects completed an ASL narrative comprehension test developed at the Salk Institute, and their performance was equal to that of deaf native signers. No subject had any history of neurological or psychiatric disease, and all gave formal consent in accordance with Federal and institutional guidelines.

Procedures

Image acquisition

All subjects underwent MR scanning in a General Electric Signa scanner operating at 1.5 T, using the following protocol: SPGR 30, TR 24, TE 7, NEX 1, FOV 24 cm, matrix 256×192 . Each of 3 individual 1NEX SPGR data sets was obtained with 124

contiguous coronal slices with thickness 1.5–1.7 mm and interpixel distance 0.94 mm. The slice thickness varied so as to be adjusted to the size of the brain and the head in order to sample the entire brain, while avoiding wrap artifacts. The three individual data sets were co-registered post hoc with Automated Image Registration (AIR 3.03) to produce a single data set, of enhanced quality, with pixel dimensions of 0.7 mm in plane and 1.5 mm between planes (Holmes et al., 1998). The MR sequences were reconstructed for each subject in 3-D using Brainvox (Damasio and Frank, 1992; Frank et al., 1997). Extracerebral voxels were edited away manually. The MR scans were used to confirm the absence of structural abnormalities, to plan the PET slice orientation, and to delineate regions of interest a priori.

PET-Brainvox (Damasio et al., 1994; Grabowski et al., 1995) was used to plan the PET slice orientation parallel to the long axis of the temporal lobes, so that the PET acquisition volume included the temporal lobes and the inferior parietal lobules in all subjects. Talairach space was constructed directly for each subject via user-identification of the anterior and posterior commissures and the midsagittal plane in Brainvox. An automated planar search routine defined the bounding box and a piecewise linear transformation was used (Frank et al., 1997), as defined in the Talairach atlas (Talairach and Tournoux, 1988). After Talairach transformation, the MR data sets were warped (AIR 5th order nonlinear algorithm) to an atlas space constructed by averaging 50 normal Talairach-transformed brains, rewarping each brain to the average, and finally averaging them again (analogous to the procedure described in Woods et al., 1999). For simplicity, we will henceforth refer to this standard space as “Talairach space”. The Talairach-transformed 3D scans of all 10 subjects were averaged. The search volume, encompassing the left inferotemporal cortices (IT) and the bilateral inferior parietal lobules (the supramarginal and angular gyri), was traced on the averaged brain, so as to establish the limits and the size of the search volume.

Positron emission tomography (PET) data were acquired with a General Electric 4096 Plus body tomograph (G.E. Medical Systems, Milwaukee, WI), yielding 15 transaxial slices with a nominal interslice interval of 6.5 mm (see Grabowski et al., 1996). For each injection, 50 mCi of [^{15}O] water was administered as a bolus through a venous catheter. Arterial blood sampling was not performed. Each subject received 8 injections containing 50 mCi of [^{15}O]water.

Experimental tasks

Each subject performed four tasks, twice each. The tasks were the following: (1) production of a classifier construction denoting the spatial relation between two objects (mostly manipulable objects) depicted by line drawings in which the figure object was colored red (see Figs. 1A and B); (2) production of spoken English prepositions denoting the spatial relation between objects; (3) production of ASL signs denoting the red-shaded manipulable objects in the stimuli presented in (1) (see Fig. 1C); and (4) production of spoken English words denoting the red-shaded manipulable objects in the stimuli presented in (2). Twenty-three stimuli were presented for each task, and the interstimulus interval for all tasks was 1.5 s. Naming objects (tasks 3 and 4) served as the control task for naming spatial relationships (tasks 1 and 2) in ASL and English, and the same stimuli (in a different order) were presented for the spatial relationship and object naming tasks.

When producing classifier constructions in task (1), the left hand represented the ground object (either a flat or a cylindrical

object), and the right hand indicated the location of the figure object, as illustrated in Fig. 1B. The configuration of the right hand depended upon the nature of the figure object, for example, a I handshape for long thin objects, an F handshape (thumb and index finger touch, remaining fingers are extended) for small flat round objects, etc. For one injection, the left hand was always in a B hand configuration (fingers together, palm down) indicating a flat surface, and the ground objects could all be represented by a B classifier handshape. For the second injection, the left hand was always in a C hand configuration (fingers together and curved, palm facing right) indicating a cylindrical object, and the ground objects were all cylindrical. The left hand remained relatively static, while the right hand was placed on top of, next to, behind, in front of, under, above, or inside of the left hand, depending upon the spatial relation described. Prior to each injection, subjects were told which hand configuration should be used to represent the ground object. Subjects were told not to name either the figure or the ground object, but to produce only the classifier predicate that expressed the spatial relation depicted in the picture.

When producing signed object names, subjects signed with their right hand in a natural “whisper mode” so that the hand did not contact the face. One-handed signing is natural for whispering and also occurs during everyday signing (e.g., when one hand is occupied). The majority of signed responses involved only the right hand; this was also true for classifier constructions because the left hand remained in the same configuration (i.e., either a B handshape or a C handshape) for each stimuli set.

For the English tasks 2 and 4, subjects were asked to overtly produce (say out loud) the English word that named the spatial relationship between the red object (the figure) and the non-colored object (the ground) or to name the red object. The order of language production tasks, ASL (tasks 1 and 3) or English (tasks 2 and 4), was blocked and counter-balanced across subjects.

Subjects’ responses were recorded during the PET study by a native ASL signer (for ASL responses) and by a hearing native English speaker (for spoken responses), and the responses were also audio and video recorded for confirmation and later analysis. The stimuli were presented from 5 s after each injection (approximately 10 s before the bolus arrived in the brain) until 40 s after each injection.

Data analysis

Reconstructed images of the distribution of radioactive counts from each injection were coregistered with each other using Automated Image Registration (AIR 3.03, Roger Woods, UCLA). 3D MR and the mean coregistered PET data were also coregistered using PET-Brainvox and Automated Image Registration (AIR) (Woods et al., 1993). PET data were Talairach-transformed as described above, masked to the coregistered MRI brain contour to exclude extracerebral voxels, and then smoothed with an isotropic 16 mm Gaussian kernel by Fourier transformation, complex multiplication, and reverse Fourier transformation. The final calculated image resolution was $18 \times 18 \times 18$ mm.

PET data were analyzed with a pixelwise linear model which estimated coefficients for global activity (covariable) and task and block/subject effects (classification variables) (Friston et al., 1995; Grabowski et al., 1996). We searched for changes in adjusted mean activity in images of t statistics generated for each of the planned contrasts. Critical t values were calculated using

Gaussian random field theory for t statistics (Worsley, 1994; Worsley et al., 1992).

The planned contrasts were as follows:

- (a) To determine whether the production of everyday spatial language in English engages the left inferior parietal lobule, naming of figure objects in English was subtracted from naming of spatial relations with prepositions. This contrast is also predicted to reveal greater activation in left inferior temporal cortex for English nouns.
- (b) To determine whether the production of spatial language in ASL engages parietal cortex bilaterally, naming of figure objects in ASL was subtracted from naming of spatial relations with classifier constructions. Because both classifier constructions and ASL nouns denote information about object type, this contrast is not expected to result in a significant difference in activation within left inferior temporal cortex.
- (c) To determine what neural regions were more active when bilinguals expressed spatial relationships in ASL than in English and what neural regions were equally active during the production of spatial language in ASL and in English, interaction and conjunction analyses were conducted, with object-naming as the baseline task for both languages.

Results

The volume of the search volume (left IT, bilateral inferior and superior parietal lobules) was 181 cm^3 (29 resels), and the critical t value was ± 3.96 for the a priori search volume (Table 1A) and ± 4.69 for the whole brain post hoc search volume (Table 1B). As predicted, the direct contrast between producing English prepositions and English nouns revealed activation within left supramarginal gyrus with two maxima for English prepositions ($-57, -48, +22$; $-57, -39, +29$), and these activation maxima were within 10 mm of that observed previously for this contrast with monolingual English speakers ($-62, -41, +27$; Damasio et al., 2001). Unlike previous results with monolingual English speakers using the same stimuli, this contrast revealed activation in right supramarginal gyrus ($+59, -34, +39$) and right angular gyrus ($+40, -75, +26$) for English prepositions. Finally, as predicted, this contrast also revealed greater activation within left posterior inferior temporal cortex for English nouns compared to prepositions ($-50, -62, -14$; see Table 1A and Fig. 2A). No additional significant differences in activation were observed for English prepositions contrasted with nouns for the whole brain analysis.

For the contrast between producing ASL classifier constructions and ASL nouns, activation maxima were observed in the left superior parietal lobule ($-33, -47, +52$; $-19, -57, +52$), right posterior intraparietal sulcus ($+34, -79, +32$), right superior parietal lobule ($+21, -61, +51$), and the right post central sulcus ($+36, -38, +53$) for classifier constructions (see Table 1A and Fig. 2B). Unlike English prepositions, the whole brain analysis revealed significant activation for ASL classifier constructions in the left lateral occipital gyrus (see Table 1B). As predicted, the contrast between ASL classifier constructions and ASL nouns did not indicate greater activation in left IT for ASL nouns. However, greater activation for ASL nouns was observed in the left inferior frontal gyrus and posterior superior temporal cortex (see Fig. 2B and Tables 1A and B).

Table 1A

Maxima for naming spatial relations contrasted with naming objects in English and in ASL in the search volume (Critical $t \pm 3.96$)

Region	English contrast		ASL contrast		Interaction analysis	
	English prepositions minus English nouns		ASL classifier constructions minus ASL nouns		Signing classifier constructions (minus signed nouns) minus saying English prepositions (minus spoken nouns)	
	T ₈₈ coordinates	Threshold t (dof)	T ₈₈ coordinates	Threshold t (dof)	T ₈₈ coordinates	Threshold t (dof)
<i>Temp. Lobe</i>						
STS/MTG L			-49 -31 -2	-4.53	-47 -28 +1	-4.31
Post. IT L	-50 -62 -14	-4.10				
<i>Parietal Lobe</i>						
SMG L	-57 -48 +22	+4.46			-54 -45 +22	-5.31
L	-57 -39 +29	+4.56				
R	+59 -34 +39	+4.03				
Angular g. R	+40 -75 +26	+4.10				
Intraparietal s. R			+34 -79 +32	+7.84		
SPL L			-33 -47 +52	+5.17		
L			-19 -57 +52	+5.66		
R			+21 -61 +51	+6.29	+35 -37 +54	+7.08
R					+18 -40 +50	+6.30
Post central s. R			+36 -38 +53	+10.48		

We conducted an interaction analysis comparing spatial language production in each language (English prepositions; ASL classifiers) minus the appropriate baseline for each language (English nouns; ASL nouns). This analysis revealed that English prepositions exhibited greater activation than ASL classifier constructions in left supramarginal gyrus (Table 1A) and in left inferior frontal cortex (Table 1B); see Fig. 2C. In addition, ASL classifier constructions exhibited greater activation than English prepositions in the right superior parietal lobule (Table 1A; Fig. 2C).

Finally, the conjunction analysis revealed a main effect of spatial language (minus noun production), with activation conjunctions in left supramarginal gyrus (-58, -37, +42), left intraparietal sulcus (-41, -45, +51), and right posterior superior parietal lobule (+11, -71, +40) (critical $t = 3.96$).

Discussion

Naming spatial relationships with English prepositions engaged left supramarginal gyrus, replicating our previous results with

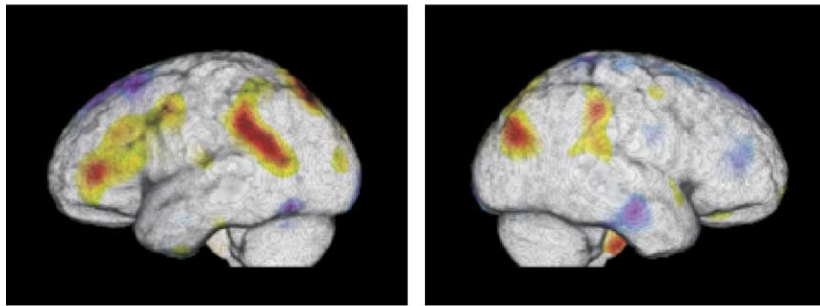
monolingual English speakers (Damasio et al., 2001). However, we also observed activation in the right inferior parietal lobule, which was not observed for monolingual English speakers under the same task conditions (see Fig. 2A). We hypothesize that this right hemisphere activation is due to life-long experience with ASL. Our previous results show that experience with ASL enhances certain spatial cognitive abilities, specifically mental rotation and image generation (Emmorey et al., 1993). Furthermore, signers exhibit a *right* hemisphere advantage for image generation, using either categorical or coordinate spatial relations representations, unlike hearing nonsigners (Emmorey and Kosslyn, 1996). Kosslyn (1987) and Kosslyn et al. (1988, 1995) argue that the left hemisphere encodes categorical spatial relations more efficiently than the right; such relations specify an equivalence class, such as “connected to” or “above.” In contrast, the right hemisphere processes coordinate spatial relations more efficiently than the left; these relations specify more gradient spatial properties, such as precise distance. The representation of categorical spatial relations has parallels to the categorical and symbolic nature of English prepositions. In contrast, the representation of coordinate spatial relations has parallels to the analogue and gradient use of signing space to

Table 1B

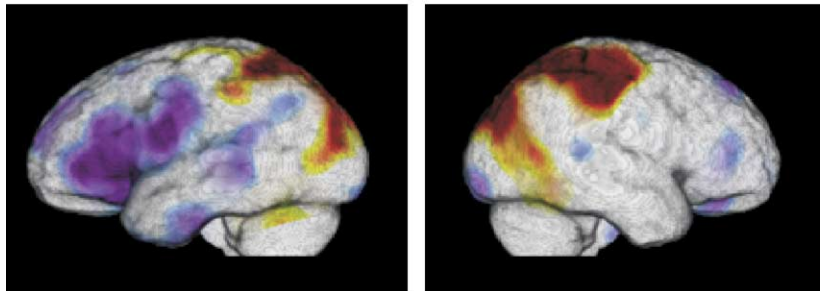
Maxima for naming spatial relations contrasted with naming objects in English and in ASL with the whole brain analysis (Critical $t \pm 4.69$)

Region	English contrast		ASL contrast		Interaction analysis	
	English prepositions minus English nouns		ASL classifier constructions minus ASL nouns		Signing classifier constructions (minus signed nouns) and saying English prepositions (minus spoken nouns)	
	T ₈₈ coordinates	Threshold t (dof)	T ₈₈ coordinates	Threshold t (dof)	T ₈₈ coordinates	Threshold t (dof)
<i>Frontal Lobe</i>						
Pole L	No differences in activation					
IFG L			-13 +54 +15	-4.89		
Precentral g. L			-38 +26 +3	-5.22	-41 +29 +9	-5.34
Temporal Lobe	No differences in activation					
STS L			-47 -4 +27	-5.12	-47 +3 -30	-5.05
Occipital Lobe	No differences in activation					
Lat. Occ. g. L			-37 -86 +20	+4.86		

A) English prepositions minus English nouns



B) ASL classifier constructions minus ASL nouns



C) Interaction analysis: ASL classifier constructions and English prepositions

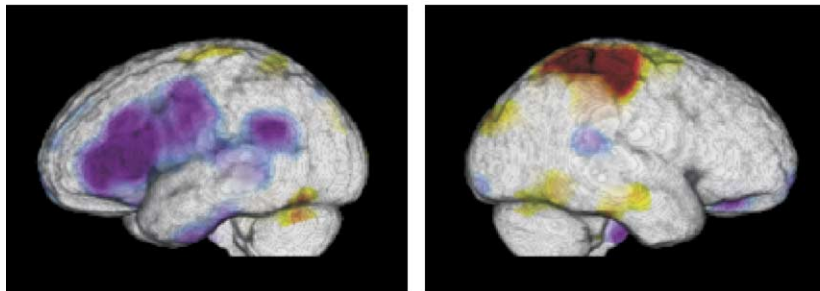


Fig. 2. Illustrations of the t statistic maps for the following planned contrasts: (A) naming spatial relationships with English prepositions and naming the figure objects in the scene, (B) depicting spatial relationships with ASL classifier constructions and naming the figure objects in the scene, and (C) the interaction results for the contrasts in (A) and (B). In the depicted color scale, the extreme red and the extreme violet colors indicate the significant activation after random field correction for multiple comparisons in the search volume (left IT, bilateral inferior and superior parietal lobules). In (A), the warm end of the palette (red) displays regions where there was more activity retrieving English prepositions than English nouns, while the cool end of the palette (purple) displays regions where there was more activity retrieving English nouns than prepositions. Similarly, in (B), red indicates areas where there was more activity for the production of ASL locative classifier constructions than for retrieving ASL nouns, and purple indicates areas where there was more activity for retrieving ASL nouns than for the production of ASL locative classifier constructions. Finally, in (C), red indicates areas where there was more activity for the production of ASL locative classifier constructions than for the retrieval of English prepositions, and blue indicates areas where there was more activity for the retrieval of English prepositions than for the production of ASL classifier constructions.

represent spatial relationships. The results of Emmorey and Kosslyn (1996) suggest that the right hemisphere plays a greater role in spatial analysis for signers than nonsigners.

We propose that right parietal cortex may be engaged when ASL-English bilinguals process spatial relationships for linguistic encoding. ASL-English bilinguals, unlike English monolinguals, may process spatial relationships for encoding in ASL, even when the task is to produce an English preposition. The right hemisphere activation observed for bilingual ASL-English speakers is not unattested in English monolingual speakers, but it occurs under conditions that set an extra demand on the encoding of spatial relationships (i.e., when objects within the scene are non-nameable). It is also possible that right hemisphere activation might not be observed when ASL-English bilinguals are clearly in a monolingual mode (e.g., no bilinguals are present) and they are

asked to produce *only* English prepositions. When bilinguals are in a monolingual mode, their other language is less accessible or active, although it is never “turned off” (Grosjean et al., 2003). A number of lines of research indicate that bilinguals are not simply two monolinguals in one body and that knowledge of a second language influences processing of a first language (Dijkstra and Van Heuven, 2002; Grosjean, 1998, 2000). We suggest that engagement of right parietal cortex when ASL-English bilinguals name everyday spatial relationships with English prepositions is due to their bilingualism. In this case, however, bilingualism takes the form of two simultaneously acquired first languages, rather than the sequential acquisition of a first and then a second language.

As predicted, the production of ASL locative classifier constructions activated parietal cortex bilaterally, replicating our

previous results with deaf ASL signers (Emmorey et al., 2002). The activation maximum in the left superior parietal lobule ($-33, -47, +52$; Table 1A) was within 10 mm of that observed for deaf signers in the left supramarginal gyrus ($-38, -45, +42$; Emmorey et al., 2002), and the activation maximum in the right superior parietal lobule ($+21, -61, +51$; Table 1A) was just 11 mm away from that observed for deaf signers ($+31, -50, +43$; Emmorey et al., 2002). Thus, the production of locative classifier constructions engages very similar parietal regions for both hearing and deaf ASL signers.

As predicted, the contrast between the production of English prepositions and English nouns revealed significant activation within left inferior temporal cortex, but the contrast between the production of ASL locative classifier constructions and ASL nouns did not. This pattern of results was predicted because for English, naming concrete entities—unlike naming spatial relationships—is hypothesized to involve neural mediation within left IT between conceptual knowledge of objects and phonological representations needed for production of the object name (Damasio et al., 2004). The production of ASL locative classifier constructions is also hypothesized to involve mediation between conceptual knowledge of objects and production of the appropriate classifier handshape morpheme, encoding object type within the classifier construction expressing a spatial relationship. Thus, the contrast between naming the figure object and expressing a spatial relationship in ASL did not reveal differential activation within left IT.

Another critical distinction between English prepositions and ASL locative classifier constructions was differential activation within the left inferior frontal gyrus (IFG). Specifically, the contrast between ASL classifier constructions and object names revealed significant activation within left inferior frontal cortex with maximum activation in Broca's area (BA 44/45) for the production of ASL object names (this is seen as a deactivation in Fig. 2B; see Table 1B). The same contrast between English prepositions and nouns did not reveal differential activation in left IFG. In addition, the interaction analysis revealed that naming spatial relationships with English prepositions differentially engaged left inferior frontal gyrus, in comparison to depicting spatial relationships with ASL locative classifier constructions (this interaction is seen as a deactivation in Fig. 2C; see Table 1B). Finally, we examined data from our previous studies in which we included a baseline task that did not place extensive requirements on lexical retrieval: subjects viewed upright or inverted unfamiliar faces and responded “yes” (or “up”) if the face was upright and “no” (or “down”) if the face was upside down. In comparison to this control task, production of both English spatial prepositions and English nouns engaged Broca's area: $-31, +24, +12$ and $-44, +22, +5$, respectively (Damasio et al., 2001; Grabowski et al., 1998). Similarly, the production of both ASL prepositions and ASL nouns in comparison to the control task engaged Broca's area: $-50, +19, +20$ and $-49, +24, +15$, respectively (these data are from Emmorey et al., 2002, but the baseline contrasts were not reported in the published study). In contrast, the production of ASL locative classifier constructions did not engage left inferior frontal cortex in comparison to the control task.

In summary, our current and previous results indicate that the production of ASL nouns, verbs (Emmorey et al., 2004), and lexical prepositions all engage Broca's area, but the production of ASL locative classifier constructions does not. One possible explanation for this somewhat surprising result is that because classifier constructions do not constitute a simple lexical category,

their production does not engage the same lexical retrieval processes that have been associated with Broca's area (e.g., Petersen et al., 1988; Thompson-Schill et al., 1997). In all our PET studies, signers and speakers were required to retrieve a distinct lexical item for each picture stimulus. However, for locative classifier constructions, subjects did not retrieve a specific lexical sign that denoted an object, action, or spatial relationship; rather, they retrieved a handshape morpheme that denoted an object *type* (e.g., long and thin). Our finding that the production of these constructions does not significantly engage Broca's area, in contrast to the production of lexical signs (including lexical prepositions), suggests that Broca's area plays a particular role in the selection and/or retrieval of specific lexical items, that is, “names” of entities, actions, and relationships.

However, another possible explanation for the lack of activation in Broca's area for locative classifier constructions is that these constructions differ from lexical signs with respect to the presence of mouth components.¹ Lexical signs are often accompanied by “mouthing,” in which a spoken word translation (or part of the word) is produced silently with the manual sign. Such mouth articulations may constitute a phonologically specified part of a sign (see Boyes-Braem and Sutton-Spence, 2001), and deaf children sometimes acquire the mouth component of a sign before they know the spoken English word upon which it is based. For example, a young deaf child might produce the “ch” mouthing for CHURCH or the “fsh” mouthing for FINISH before acquiring the English words “church” or “finish.” Lexical signs (nouns, verbs, and prepositions) are much more likely to be produced with a mouth component, compared to locative classifier constructions. The mouth component that most often accompanies an ASL locative classifier construction is a slight protrusion of the lips (the semantics of this expression are not well understood). We did not film our subjects' faces, but it is likely that more varied mouthing was produced with lexical signs than with locative classifier constructions. Thus, it is possible that the lack of activation in Broca's area for locative classifier constructions could be related to the lack of accompanying mouth articulations. However, the activation observed within Broca's area for the retrieval of lexical signs is fairly anterior in BA 45/47. If the observed activation was due to articulatory features of lexical signs, more posterior activation (BA 44) would be predicted based on the findings of Horwitz et al. (2003). In a PET study of ASL-English bilinguals using rest and articulatory baselines, Horwitz et al. (2003) concluded that BA 44 was involved in phonetic aspects of articulation for sign and for speech, whereas BA 45 was more involved in modality-independent aspects of language production.

Finally, the interaction analysis revealed that the production of English prepositions engaged left supramarginal gyrus ($-54, -45, +22$) to a greater extent than ASL classifier constructions (again, this is seen as a deactivation in Fig. 2C; see Table 1A). This result is consistent with our previous finding that activation within left SMG for the production of spatial language by monolingual English speakers was inferior to that observed for deaf ASL signers. Thus, the activation within this more inferior region of the left SMG appears to reflect processing that is specific to encoding spatial information with closed-class English prepositions. Interestingly, the conjunction analysis revealed that spatial language in

¹ We thank an anonymous reviewer for bringing this possibility to our attention.

both English and ASL engaged a more superior region within left SMG (−58, −37, +42). Activation in this more superior region of left SMG may reflect processes involved in the more general, modality-independent linguistic encoding of spatial information.

The interaction analysis also revealed that production of ASL locative classifier constructions differentially engaged the right superior parietal lobule (+35, −37, +54; +18, −40, +50; see [Table 1A](#); [Fig. 2C](#)). There were no regions within the right hemisphere that were more engaged during the production of English prepositions than ASL classifier constructions. These results complement our previous findings from separate studies, which indicated that depicting spatial relationships with ASL locative classifier constructions engaged right parietal cortex, but naming everyday spatial relationships with English prepositions did not. In addition, however, the conjunction analysis revealed that a more mesial and posterior region within right superior parietal cortex was equally engaged during the production of English prepositions and ASL classifier constructions (+11, −71, +40). We speculate that this region of joint activation within the right hemisphere may arise from ASL-English bilinguals' more gradient encoding of spatial relationships to be expressed linguistically. We further hypothesize that the more anterior and lateral activation observed only during the production of ASL locative classifier constructions may reflect the engagement of right parietal cortex in the visual-motoric transformation between the visually depicted spatial relationship and the isomorphic manual representation of this spatial relationship.

In summary, the conjunction analysis revealed that parietal cortex was engaged bilaterally during the production of both English prepositions and ASL locative classifier constructions. We hypothesize that the activation within the left supramarginal gyrus reflects general, modality-independent linguistic encoding of spatial information. Activation in this region was observed when deaf signers produced ASL locative constructions and when hearing nonsigners produced English prepositions ([Damasio et al., 2001](#); [Emmorey et al., 2002](#)). In contrast, we hypothesize that the activation observed within the right hemisphere when ASL-English bilinguals produced English prepositions is due to their bilingualism—right hemisphere activation was not observed for monolingual English speakers under the same task conditions ([Damasio et al., 2001](#)). These findings suggest caution when interpreting neuroimaging results from bilingual subjects because the pattern of activation may not mirror that of monolingual subjects.

Finally, the production of spatial language in ASL and in English differed in both expected and unexpected ways. First, as predicted, the interaction analysis showed that right superior parietal cortex was more engaged during the production of locative classifier constructions than English prepositions. We have hypothesized that this activation reflects the visual-motoric transformation between locations of objects within a scene and locations of the hands in signing space. Second, as predicted, the evidence indicates that the production of ASL classifier constructions engages left inferior temporal cortex, unlike English prepositions. Left IT may be engaged because classifier hand-shapes encode information about object type. Third, and somewhat surprisingly, the production of English prepositions engaged Broca's area, but ASL locative classifier constructions did not. One possible explanation for this result is that the production of these constructions does not involve the lexical retrieval of the *name* of an object, action, or spatial relation. Together, these results

indicate that the neural correlates of spatial language in English and American Sign Language are non-identical and reflect linguistic and modality-specific processing requirements.

Acknowledgments

This research was supported by a grant from the National Institute on Deafness and other Communicative Disorders, 1 P50 DC 03189, awarded to the University of Iowa and to The Salk Institute for Biological Studies. We thank Helsa Borinstein and Jon Spradling for their help in conducting the study. We are particularly grateful to the native ASL-English bilinguals who participated in the study.

References

- Boyes-Braem, P., Sutton-Spence, R., 2001. *The Hands are the Head of the Mouth*. Signum-Verlag, Hamburg.
- Braun, A.R., Guillemin, A., Hosey, L., Varga, V., 2001. The neural organization of discourse: an H215O PET study of narrative production in English and American Sign Language. *Brain* 124, 2028–2044.
- Damasio, H., Frank, R., 1992. Three-dimensional in vivo mapping of brain lesions in humans. *Arch. Neurol.* 49, 137–143.
- Damasio, H., Grabowski, T.J., Frank, R., Knosp, B., Hichwa, R.D., Watkins, G.L., Ponto, L.L.B., 1994. PET-Brainvox, a technique for neuroanatomical analysis of positron emission tomography images. In: Uemura, K., Lassen, N.A., Jones, T., Kanno, I. (Eds.), *Quantification of Brain Function*. Elsevier, Amsterdam, pp. 465–474.
- Damasio, H., Grabowski, T.J., Tranel, D., Ponto, L.L.B., Hichwa, R.D., Damasio, A.R., 2001. Neural correlates of naming actions and of naming spatial relations. *NeuroImage* 13, 1053–1064.
- Damasio, H., Tranel, D., Grabowski, T.J., Adolphs, R., Damasio, A., 2004. Neural systems behind word and concept retrieval. *Cognition* 92, 179–229.
- Dijkstra, T., Van Heuven, W.J.B., 2002. The architecture of the bilingual word recognition system: from identification to decision. *Biling. Lang. Cogn.* 5 (3), 175–197.
- Emmorey, K., 2003. *Perspectives on Classifier Constructions in Signed Languages*. Lawrence Erlbaum and Associates, Mahwah, NJ.
- Emmorey, K., Herzig, M., 2003. Categorical versus gradient properties of classifier constructions in ASL. In: Emmorey, K. (Ed.), *Perspectives on Classifier Constructions in Signed Languages*. Lawrence Erlbaum Associates, Mahwah NJ, pp. 222–246.
- Emmorey, K., Kosslyn, S., 1996. Enhanced image generation abilities in deaf signers: a right hemisphere effect. *Brain Cogn.* 32, 28–44.
- Emmorey, K., Kosslyn, S., Bellugi, U., 1993. Visual imagery and visual-spatial language: enhanced imagery abilities in deaf and hearing ASL signers. *Cognition* 46, 139–181.
- Emmorey, K., Corina, D., Bellugi, U., 1995. Differential processing of topographic and referential functions of space. In: Emmorey, K., Reilly, J. (Eds.), *Language, Gesture, and Space*. Lawrence Erlbaum Associates, Hillsdale, NJ, pp. 43–62.
- Emmorey, K., Damasio, H., McCullough, S., Grabowski, T., Ponto, L., Hichwa, R., Bellugi, U., 2002. Neural systems underlying spatial language in American Sign Language. *NeuroImage* 17, 812–824.
- Emmorey, K., Grabowski, T., McCullough, S., Damasio, H., Ponto, L., Hichwa, R., Bellugi, U., 2004. Motor-iconicity of sign language does not alter the neural systems underlying tool and action naming. *Brain Lang.* 89 (1), 27–37.
- Frank, R.J., Damasio, H., Grabowski, T.J., 1997. Brainvox: an interactive, multimodal visualization and analysis system for neuroanatomical imaging. *NeuroImage* 5, 13–30.
- Friston, K.J., Holmes, A.P., Worsley, K.J., Poline, J.-B., Frith, C.D.,

- David, A.S., 1995. Statistical parametric maps in functional imaging: a general linear approach. *Hum. Brain Mapp.* 2, 189–210.
- Grabowski, T.J., Damasio, H., Frank, R., Hichwa, R., Boles Ponto, L.L., Watkins, G.L., 1995. A new technique for PET slice orientation and MRI-PET coregistration. *Hum. Brain Mapp.* 2, 123–133.
- Grabowski, T.J., Frank, R.J., Brown, C.K., Damasio, H., Boles Ponto, L.L., Watkins, G.L., Hichwa, R.D., 1996. Reliability of PET activation across statistical methods, subject groups, and sample sizes. *Hum. Brain Mapp.* 4, 23–46.
- Grabowski, T.J., Damasio, H., Damasio, A.R., 1998. Prefrontal and premotor correlates of category-related lexical retrieval. *NeuroImage* 7, 232–243.
- Grosjean, F., 1998. Studying bilinguals: methodological and conceptual issues. *Biling. Lang. Cogn.* 1, 131–149.
- Grosjean, F., 2000. The bilingual's language modes. In: Nicol, J. (Ed.), *One Mind, Two Languages: Bilingual Language Processing*. Blackwell, Oxford, pp. 1–22.
- Grosjean, F., 2000. The bilingual's language modes. In: Nicol, J. (Ed.), *One Mind, Two Languages: Bilingual Language Processing*. Blackwell, Oxford, pp. 1–22.
- Grosjean, F., Peng, L., Münte, T.F., Rodriguez-Fornells, A., 2003. Imaging bilinguals: when the neurosciences meet the language sciences. *Biling. Lang. Cogn.* 6 (2), 159–165.
- Holmes, C.J., Hoge, R., Collins, L., Woods, R.P., Evans, A.C., Toga, A.W., 1998. Enhancement of MR images using registration for signal averaging. *J. Comput. Assist. Tomogr.* 22, 324–333.
- Horwitz, B., Amunts, K., Bhattacharyya, R., Patkin, D., Jeffries, K., Zilles, K., Braun, A., 2003. Activation of Broca's area during the production of spoken and signed language: a combined cytoarchitectonic mapping and PET analysis. *Neuropsychologia* 41, 1868–1876.
- Kosslyn, S.M., 1987. Seeing and imagining in the cerebral hemispheres: a computational approach. *Psychol. Rev.* 94, 148–175.
- Kosslyn, S., Cave, C., Provost, D., Von Gierke, S., 1988. Sequential processes in image generation. *Cogn. Psychol.* 20, 319–343.
- Kosslyn, S.M., Maljkovic, V., Hamilton, S.E., Horwitz, G., Thompson, W.L., 1995. Two types of image generation: evidence for left- and right-hemisphere processes. *Neuropsychologia* 33, 1485–1510.
- MacSweeney, M., Woll, B., Campbell, R., Calvert, G.A., McGuire, P.K., David, A.S., Simmons, A., Brammer, M.J., 2002. Neural correlates of British Sign Language comprehension: spatial processing demands of topographic language. *J. Cogn. Neurosci.* 14 (7), 1065–1075.
- Petersen, S.E., Fox, P.T., Posner, M.I., Mintun, M.A., Raichle, M.E., 1988. Positron emission tomographic studies of the cortical anatomy of single-word processing. *Nature* 331, 585–589.
- Posner, M.I., Petersen, S.E., 1990. The attention system of the human brain. *Ann. Rev. Neurosci.* 13, 25–42.
- Talairach, J., Tournoux, P., 1988. *Co-Planar Stereotaxic Atlas of the Human Brain*. Thieme, New York.
- Talmy, L., 2000. *Toward a Cognitive Semantics: Concept Structuring Systems*. The MIT Press, Cambridge, MA.
- Thompson-Schill, S.L., D'Esposito, M., Aguirre, G.K., Farah, M.J., 1997. Role of left inferior prefrontal cortex in retrieval of semantic knowledge: a reevaluation. *Proc. Natl. Acad. Sci.* 94, 1472–14797.
- Ungerleider, L.G., Mishkin, M., 1982. Two cortical visual systems. In: Ingle, D.J., Goodale, M.A., Mansfield, R.J.W. (Eds.), *Analysis of Visual Behavior*. MIT Press, Cambridge, MA, pp. 549–589.
- Woods, R.P., Mazziotta, J.C., Cherry, S.R., 1993. MRI-PET registration with automated algorithm. *J. Comput. Assist. Tomogr.* 17, 536–546.
- Woods, R.P., Daprett, M., Sicotte, N.L., Toga, A.W., Mazziotta, J.C., 1999. Creation and use of a Talairach-compatible atlas for accurate, automated, nonlinear intersubject registration, and analysis of functional imaging data. *Hum. Brain Mapp.* 8, 73–79.
- Worsley, K.J., 1994. Local maxima and the expected Euler characteristic of excursion sets of c_2 , F , and t fields. *Adv. Appl. Probab.* 26, 13–42.
- Worsley, K.J., Evans, A.C., Marrett, S., Neelin, P., 1992. A three dimensional statistical analysis for CBF activation studies in human brain. *J. Cereb. Blood Flow Metab.* 12, 900–918.